

RESEARCH ARTICLE

Evolution of the speech-ready brain: The voice/jaw connection in the human motor cortex

Steven Brown¹  | Ye Yuan¹ | Michel Belyk²

¹Department of Psychology, Neuroscience & Behaviour, McMaster University, Hamilton, Ontario, Canada

²Department of Speech Hearing and Phonetic Sciences, University College London, London, UK

Correspondence

Steven Brown, Department of Psychology, Neuroscience & Behaviour, McMaster University, 1280 Main St. West, Hamilton, ON L8S 4K1, Canada.
Email: stebro@mcmaster.ca

Funding information

Natural Sciences and Engineering Research Council (NSERC), Grant/Award Number: 371336

Abstract

A prominent model of the origins of speech, known as the “frame/content” theory, posits that oscillatory lowering and raising of the jaw provided an evolutionary scaffold for the development of syllable structure in speech. Because such oscillations are nonvocal in most nonhuman primates, the evolution of speech required the addition of vocalization onto this scaffold in order to turn such jaw oscillations into vocalized syllables. In the present functional MRI study, we demonstrate overlapping somatotopic representations between the larynx and the jaw muscles in the human primary motor cortex. This proximity between the larynx and jaw in the brain might support the coupling between vocalization and jaw oscillations to generate syllable structure. This model suggests that humans inherited voluntary control of jaw oscillations from ancestral species, but added voluntary control of vocalization onto this via the evolution of a new brain area that came to be situated near the jaw region in the human motor cortex.

KEYWORDS

evolution, fMRI, jaw, larynx, speech, vocalization

1 | INTRODUCTION

The capacity to externalize linguistic ideas through speech is one of the defining features of the human species. While speech is not the only means by which language can be externalized, it is the dominant one used in everyday communication. Speech is characterized as being a combinatorial phonological system (Jackendoff, 2002) that employs a relatively small pool of phonemic units (i.e., vowels and consonants) that get combined to form syllables, which themselves get combined to form polysyllabic words. Languages contain an average of about 30 such phonemic units (Maddieson, 2005a, 2005b). While the phonemic composition of individual syllables varies strikingly across languages—from a single vowel (“a”) to the consonant clusters of the Germanic languages like English (“straps”)—the most universal structure is a consonant/vowel (CV) combination (MacNeilage, 1998, 2008), as occurs in the phonetic forms of words such as go, follow, happily, and vicinity, where consonants and vowel-sounds alternate with one another (irrespective of the spelling that is used to represent these sounds).

One of the most influential ideas about the origins of speech is MacNeilage's frame/content theory (MacNeilage, 1998, 2008). It is predicated on the idea that the cycling between consonants and vowels, as in a sequence of CV syllables, occurs via an oscillatory lowering and raising of the jaw, as is found in the baby's babble sound of ba-ba-ba. Such cycling contrasts with the calling systems of non-human mammals, which generally only use the open configuration for calling (MacNeilage, 1998). Hence, syllable formation in humans is built on a process of *mandibular oscillatory cycling* between the closed (consonants) and open (vowels) configurations of the vocal tract. It is this mandibular cycling that provides the “frame” for the syllable, whereas movements of the other oral articulators (the lips, tongue, and soft palate) contribute to the “content” that determines the specific character of the phoneme (e.g., ma vs. ba). Interestingly, mandibular cycling is not just conserved between humans and nonhuman primates, but seems to be a stable physiological feature of all tetrapods (Granatosky et al., 2019).

MacNeilage (1998) proposed that an evolutionary precursor of the oscillatory cycling of syllable framing could be found in “a putative

intermediate form present in many other higher primates, namely, visuofacial communicative cyclicities such as lipsmacks, tonguesmacks, and teeth chatters" (p. 499). MacNeilage proposed that these gestures themselves evolved from ingestion-related cyclicities of the mandible related to mastication. Communicative oscillations in nonhuman primates are typically nonvocal. Any sound that accompanies these communications is generally produced by percussive sounds of the oral effectors, rather than through phonation at the larynx; an exception is found in the "wobble" of gelada baboons, in which a "moan" vocalization occurs during some lip smacking (Bergman, 2013). This stands in contrast to human speech, where vibration of the vocal folds in the larynx is the primary sound-source for both speaking and singing. Therefore, the transition from a proposed visuofacial precursor to the novel capacity for syllable production in humans would require the addition of vocalization onto the mandibular cycling present in visuofacial gestures in nonhuman primates so as to create the *voice/jaw coupling* that underlies syllable production. While the jaw muscles are under voluntary control in nonhuman primates, vocalization is much less so. Nonhuman primates are poor vocal learners, showing some capacity for vocal usage learning, but not vocal production learning (Fitch & Hauser, 2002; Loh, Petrides, Hopkins, Procyk, & Amiez, 2017; Townsend & Zuberbuhler, 2009). Therefore, a key requirement for the evolution of speech—and a missing link in the frame/content theory—is the emergence of a neural mechanism for the voluntary control of vocalization in humans.

This mechanism resides in the larynx motor cortex (LMC), which is the primary cortical center for the control of phonation and thus vocalization in the human brain (Bouchard, Mesgarani, Johnson, & Chang, 2013; Breshears, Molinaro, & Chang, 2015; Brown, Ngan, & Liotti, 2008; Dichter, Breshears, Leonard, & Chang, 2018; Simonyan, Ostuni, Ludlow, & Horwitz, 2009). The LMC is located in the primary motor cortex of the precentral gyrus, and gives rise to a descending corticobulbar projection to the nucleus ambiguus in the medulla (Iwatsubo, Kuzuhara, & Kanemitsu, 1990; Kuypers, 1958a, 1958b), which itself sends out motor neurons to the skeletal muscles of the larynx via the branchiomotor division of the vagus nerve. Penfield and Boldrey's (1937) classic analysis of the homunculus of the human primary motor cortex through neurosurgical stimulation of the brain of awake patients assigned vocalization (as a behavioral proxy for the intrinsic laryngeal muscles) to a large swath of the orofacial motor cortex, rather than to a unique location in the motor cortex that they did for the other effectors of the body, including the lips, jaw, and tongue.

A clarification of the localization of the human LMC changed in the 21st century with the first neuroimaging studies looking specifically at laryngeal functioning (reviewed in Belyk & Brown, 2017; Conant, Bouchard, & Chang, 2014; Simonyan & Horwitz, 2011). For example, Rödel et al. (2004) employed the combination of transcranial magnetic stimulation and electromyography to permit the elicitation of motor responses from two of the intrinsic laryngeal muscles that contribute to the control of vocal pitch. In an fMRI experiment, Loucks, Poletto, Simonyan, Reynolds, and Ludlow (2007) observed that vocalization engaged the same area of the motor cortex as silent

expiration, suggesting that the motor control of the laryngeal muscles is highly integrated with the driving force for vocalization, namely expiration. Brown et al. (2008) performed an fMRI study aimed at identifying a specific somatotopic location for the larynx in the human motor cortex, given the uncertainties inherent in Penfield and Boldrey's (1937) findings. They carried out a comparison between vocalization and nonvocal laryngeal movements (i.e., forceful adduction of the vocal folds via glottal stops) in the same participants. As a somatotopic reference for the articulators, they also had participants perform lip and tongue movements. All of the laryngeal tasks led to highly overlapping activations in a region of primary motor cortex that Loucks et al. (2007) had previously identified as integrating vocal and expiratory functions, an area that Brown et al. dubbed the "larynx-phonation area." This region was found to be directly adjacent to the somatotopic lip area in the dorsal part of the orofacial motor cortex. In other words, the area controlling phonation was found to be close to, but distinct from, an area for the control of articulation. Belyk and Brown (2014) later found that this same region contained a representation of not only the intrinsic musculature of the larynx, but also the extrinsic musculature that moves the entire larynx vertically within the airway, although more-ventral regions of the motor cortex made a stronger contribution to such vertical movement. Overall, it appears that evolutionary reorganization of the human motor cortex has brought the three major components of vocalization—namely, expiration, phonation, and articulation—into close proximity, an organization that is quite different from that of nonhuman primates (Belyk & Brown, 2017).

Brown et al. (2008) proposed that, because the LMC that they and others (Loucks et al., 2007; Rödel et al., 2004) had characterized in the human brain occurs in a markedly different location from the monkey LMC—which is found in the ventral premotor cortex in both Old World and New World monkeys (Hast, Fischer, & Wetzel, 1974; Hast & Milojkvic, 1966; Jürgens, 1974)—the human area must have undergone an evolutionary migration from its the ancestral location in monkeys to its human location adjacent to the somatotopic lip area in the orofacial motor cortex. More-recent work has suggested that the relevant evolutionary change may have been less of a migration per se as a duplication-and-migration event (Belyk & Brown, 2017), since neurosurgical work has suggested that the human motor cortex contains, in addition to the human-specific LMC that Loucks et al. (2007) and Brown et al. (2008) characterized, a second larynx area located in the ventral part of the motor cortex, leading to a distinction between the dorsal LMC (dLMC) and the ventral LMC, respectively (Bouchard et al., 2013; Breshears et al., 2015; Pfenning et al., 2014).

Given this reorganization of the human motor cortex for the control of vocalization, one can reasonably ask why the dLMC came to occupy the specific location that it currently has in the human brain. Brown et al. (2008) argued that the proximity of the dLMC to the lip area might suggest that the LMC came to develop a coupling to the muscles controlling articulation, since articulation is linked with phonation during speech production. However, a more specific hypothesis, following from the frame/content theory, is that the dLMC came to be situated proximate to the jaw muscles in order to support voice/

jaw coupling during syllable production. A first step toward exploring this idea is to understand the neural control of jaw movement in the primary motor cortex.

The muscles that control jaw movement are grouped antagonistically into muscles that lower the jaw and thereby open the vocal tract—so-called *depressor* muscles—and muscles that raise the jaw and close the vocal tract, so-called *elevator* muscles (Seikel, King, & Drumwright, 2010). The jaw depressors include the mylohyoid, geniohyoid, and the anterior belly of the digastric muscle, while the jaw elevators include the masseter, temporalis, and medial pterygoid muscles. Movements of the jaw and larynx are coupled during speech production, since the timing of their movements constrain one another (Gracco & Löfqvist, 1994) and since they have mutually supporting roles in critical biological functions such as swallowing (Ardran & Kemp, 1952). Indeed, some of the jaw depressors have a secondary function in raising the larynx within the airway. These muscles extend downward from the mandible toward the hyoid bone, a bony structure with muscular connections to the larynx. Contraction of this group of muscles draws the mandible and hyoid bone together, simultaneously lowering the jaw and raising the larynx. Either of these movements can be suppressed if antagonistic muscle groups resist them. For example, jaw depression can occur without larynx elevation if infra-hyoid laryngeal muscles are engaged to resist laryngeal elevation. Conversely, laryngeal elevation can occur without jaw depression if the downward movement of the jaw is resisted by the jaw elevators (Gray, 1918; Seikel et al., 2010).

An understanding of the neural control of jaw movement in humans has come from two related sources: electrical stimulation studies in neurosurgical experiments and noninvasive neuroimaging experiments using functional magnetic resonance imaging (fMRI). Seminal studies by Penfield and colleagues during the first half of the 20th century carried out invasive electrical stimulation of the motor cortex in patients undergoing surgical treatments for epilepsy (Penfield & Boldrey, 1937). Electrical stimulation of the primary motor cortex established a somatotopic map of the body in which the orofacial muscles occupy the ventral third of the precentral gyrus. Penfield and Boldrey (1937) found that movements of the jaw were elicited from an area dorsal to the tongue, but ventral to the lips. Stimulation often elicited an open/close cycle of the jaw. Isolated jaw depression or elevation was observed in some cases, although with no clear separation between the sites that elicited either movement. Recent neurosurgical research has replicated the localization of the jaw in the motor cortex (Bouchard et al., 2013). However, it should be noted that these neurosurgical experiments have only been able to stimulate superficial cortical sites on the precentral gyrus, and that more-invasive procedures would be required to stimulate the motor cortex within the central sulcus, which contains much of the primary motor cortex, including the major activation peaks for the dLMC in fMRI experiments (Brown et al., 2008; Loucks et al., 2007).

Looking now to neuroimaging studies employing PET and fMRI, the vast majority of work on the control of jaw movement in humans has focused on the process of chewing (mastication) or on repetitive occlusal movements of the jaw and thus the elevator muscles of the

jaw (e.g., Iida et al., 2010; Jiang, Liu, Liu, Jin, & Liu, 2010; Lotze, Domin, & Kordass, 2017; Onozuka et al., 2002). This has often occurred in the context of dental studies. The activation coordinates of the jaw elevators in the primary motor cortex vary throughout the orofacial motor cortex, with some studies demonstrating peaks more ventrally and some more dorsally, but consistent with the overall localization of the jaw muscles based on neurosurgical stimulation studies. The only study that we are aware of that has examined the process of jaw lowering is that of Grabski et al. (2012). Importantly, these authors demonstrated that jaw lowering produced activation peaks highly proximate to those for vocalization through vowel production. We revisit these findings in the present study by adding jaw elevation (clenching) as an additional condition in order to see if the voice overlaps with the jaw area in general or if there is a greater proximity to jaw lowering, since this dimension of jaw movement is functionally associated with speech production, whereas jaw raising is mainly linked to bite force during chewing.

To what extent is the localization of the jaw motor cortex in humans shared with nonhuman primates? Leyton and Sherrington (1917) performed electrical stimulation of the motor cortex in three species of great apes (orangutans, gorillas, and chimpanzees), and demonstrated that the jaw elevators and jaw depressors have adjacent but distinct representations in the motor cortex. In particular, the jaw elevators for mastication were shown to be located anterior and dorsal to the jaw depressor muscles. The jaw area in these great apes was found to be situated in between stimulation sites for the tongue ventrally and the lips dorsally. This overall pattern is consistent with the somatotopy of these muscles in the human brain (Bouchard et al., 2013; Penfield & Boldrey, 1937), arguing for a general conservation of the somatotopic organization of what will become the muscles of articulation in humans. More-recent electrophysiological work in Old World monkeys (but not apes) has identified a separate jaw-controlling region in the most ventral part of the motor cortex specifically associated with chewing and thus jaw elevation (Hatanaka, Tokuno, Nambu, Inoue, & Takada, 2005; Huang, Hiraba, Murray, & Sessle, 1989; Sessle, 2011; Sessle, Avivi-Arber, & Murray, 2015).

The frame/content theory is predicated on the phylogenetic notion that mandibular oscillations in nonhuman primate visuofacial communication provided the evolutionary scaffold for the emergence of syllable structure in humans. There are many such behaviors in primates, including lip smacking, tongue smacking, teeth chatters, and raspberries (Bianchi, Reyes, Hopkins, Tagliatalata, & Sherwood, 2016; Ghazanfar & Takahashi, 2014; Ghazanfar, Takahashi, Mathur, & Fitch, 2012; Hopkins, Tagliatalata, & Leavens, 2007; Morrill, Paukner, Ferrari, & Ghazanfar, 2012). Such actions involve coordinated movements of the jaw, lips, and tongue (Ghazanfar et al., 2012). Given that such behaviors are generally voiceless, the critical evolutionary step to develop syllable structure from a precursor of mandibular oscillations is to add vocalization onto this, creating an evolutionary transition from lip smacking to something like the ba-ba-ba sound of human babbling by means of voice/jaw coupling. The key question is whether this evolution required changes to the vocal tract, brain, or both. Recent observations indicate that the vocal tract of nonhuman

primates is in fact capable of producing the movements for a wide range of human speech sounds (Boë et al., 2019; Fitch, Tecumseh, Boer, Mathur, and Ghazanfar, 2016), suggesting that the critical evolution for speech production is more related to changes in the brain than to changes in the vocal tract. As Fitch et al. (2016) argued, monkeys have “a speech-ready vocal tract but lack a speech-ready brain to control it” (p. 1).

The primary objective of the present study was to employ functional neuroimaging methods to explore the conditions of the speech-ready brain in humans by examining the somatotopic relationship between the voice and jaw representations in the human motor cortex. In addition, we sought to contextualize jaw somatotopy by examining the relative localizations of the control of jaw depression and jaw elevation for the first time in humans. Based on the discussion presented above, we predicted that there would be a greater somatotopic proximity between the voice and the jaw *lowering* muscles than that with the jaw elevator muscles, since the lowering muscles are more important for speech production, whereas the elevator muscles are most important for generating biting force for chewing. If such a result were obtained, it might help explain why the dorsal LMC came to occupy the novel location that it has assumed in the human brain, namely to increase the proximity of the voice to the jaw muscles to support voice/jaw coupling during syllable production. It would also provide the missing link for the frame/content theory by arguing that a novel brain area mediating voluntary control of vocalization was added onto existing neural circuitry for mandibular oscillations, permitting a transition from the capacity for nonvocal lip smacking to one for vocal syllable production.

2 | METHODS

2.1 | Participants

Twenty-three participants (12 females, 11 males), with a mean age of 22.3 ± 3.0 years, participated in the study after giving written informed consent (Hamilton Integrated Research Ethics Board, St. Joseph's Hospital). Each individual was without neurological or psychiatric illness. Participants were all native English speakers, but were unselected with regard to handedness. Two female participants were left-handed. Participants were recruited by means of word of mouth, and were compensated monetarily for their participation.

2.2 | Tasks

Participants underwent a one-hour training session on a day prior to the scanning session in order to learn how to perform the tasks in a highly controlled manner in a supine position with a minimum of head, face, and body movement. During fMRI scanning, participants performed three oral tasks (one task per fMRI run), each one according to a blocked design of 16 s of a fixation condition and 16 s of an oral task during a 6'24" run. The task order was randomized across scans.

All tasks were performed with the eyes open. (1) *Vocalization* using the schwa vowel. Participants were instructed to produce the schwa vowel on a comfortable pitch of their choice with their teeth together, but with a very small lip opening so as to permit oral air flow and thereby avoid humming. Vocalization was carried out as breath phrases of 4–6 pitches, followed by a gentle and controlled nasal inspiration. This was done repeatedly during the 16 s task epoch. The recommended rate of pitch production was 1 Hz, as practiced during the training session. (2) *Jaw elevation* (teeth clenching). Participants were instructed to gently clench their teeth together, doing so using breath cycles of 4–6 clenches at a time, followed by a nasal inspiration. This was done repeatedly during the 16 s task epoch. The recommended rate of clenching was 1 Hz. Participants were instructed to do this in a gentle enough manner so as to avoid contracting their facial muscles. This was verified for each participant during the training session. (3) *Jaw lowering*. Participants were instructed to gently lower their jaw, doing so using breath cycles of 4–6 lowerings at a time, followed by a nasal inspiration. This was done repeatedly during the 16 s task epoch. The recommended rate of jaw lowering was 1 Hz. Participants were instructed to do this in a gentle enough manner so as to avoid contracting their facial muscles. This was verified during the training session. In order to make the lowering movement more closely matched to the clenching task, we instructed participants to begin the jaw-lowering blocks with the jaw nearly fully lowered. In this way, jaw lowering engaged the jaw depressors with minimal downward displacement, comparably to how jaw clenching engaged the jaw elevators with minimal upward displacement. If participants had performed jaw lowering from a closed-mouth starting position, then this would have engaged the jaw elevator muscles much more so than the modified task did. As a result of this change, the mouth was kept in its open starting position during the fixation epochs. Participant were trained to the point that they felt comfortable performing this task in a supine position.

2.3 | Image acquisition and data analysis

Functional images sensitive to the blood-oxygen-level-dependent (BOLD) signal were collected with a gradient-echo echo planar imaging (EPI) pulse sequence using standard parameters (TR = 2000 ms, TE = 45 ms, flip angle = 90° , 31 slices per volume, 4 mm slice thickness, no slice gap, matrix size = 64×64 , field of view = 24 cm, voxel size = $3.75 \text{ mm} \times 3.75 \text{ mm} \times 4 \text{ mm}$), effectively covering the whole brain. A total of 192 brain volumes was acquired over 6 min and 24 s of scan time, corresponding with 12 alternations between 16 s epochs of fixation and 16 s epochs of task. Anatomical T_1 images were collected for each participant (3D-FSPGR, IR-prepped, TI = 900 ms; TE = 3.22 ms; flip angle = 9° ; receiver bandwidth = 31.25 kHz; NEX = 1; slice thickness = 1 mm; slice gap = 0 mm; FOV = 24 cm; slices = 164; matrix size = 512×512).

Functional image analyses were conducted using BrainVoyager QX (version 2.8.0, Brain Innovation). Images were reconstructed offline, and the scan series was realigned and motion-corrected. During

the preprocessing stage, a temporal high-pass filter was applied at a frequency of 0.0078 Hz, or 2 cycles per scan, using the GLM-Fourier algorithm. 3D spatial smoothing was performed using a Gaussian filter with a FWHM kernel size of 4 mm. Following realignment, each functional scan was normalized to the Talairach template (Talairach & Tournoux, 1988). The BOLD response for each task was modeled as the convolution of a 16 s boxcar with a synthetic hemodynamic response function composed of two gamma functions. The six head-motion parameters were included as nuisance regressors in the analysis. In a first-level fixed-effects analysis, beta weights associated with the modeled hemodynamic responses were computed to fit the observed BOLD-signal time course in each voxel for each participant using the general linear model, as corrected for multiple comparisons using a Bonferroni correction at a threshold of $p < .05$ ($k = 4$). In a second-level group analysis, images for each task versus fixation contrast were brought forward into a random effects analysis. The resulting statistical parametric maps were interpolated to 1 mm isotropic voxels to facilitate comparison between conditions. These analyses were corrected for multiple comparisons using the false discovery rate at $q < .05$ ($k = 4$). Talairach coordinates of the activation peaks were extracted using NeuroElf (neuroelf.net).

Region-of-interest (ROI) analysis was carried out by creating spheres of 3 mm radius based on the activation peaks in the sulcal

component of the dorsal LMC for the vocalization task, namely Talairach coordinates $-41, -19, 38$ and $42, -19, 38$ in the left and right hemispheres, respectively. The coordinates for the gyral component of the dorsal LMC were $-56, -5, 43$ and $55, -7, 45$ in the left and right hemispheres, respectively. Note that we will refer to the dorsal LMC as simply the LMC in Section 3 and in Figures 1–3, since the present work focuses exclusively on the dorsal LMC, with no comparison to the ventral LMC.

3 | RESULTS

The fMRI results are shown in Figure 1, with Talairach coordinates for the activations in the motor cortex shown in Table 1 (the complete activation coordinates can be found in Table S1). While group data are shown here, the results were highly consistent across all of the individual participants. The results in Figure 1 are shown as logical images in order to demonstrate potential overlap between pairs of analyses. Figure 1a,b reveal that vocalization gave the same two-peak structure for the LMC as the structure reported in Brown et al. (2008), with bilateral peaks located deep in the central sulcus in Brodmann area (BA) 4 (left panel), and a right-dominant peak located more superficially and anteriorly in BA 6 (right panel). We will refer to these

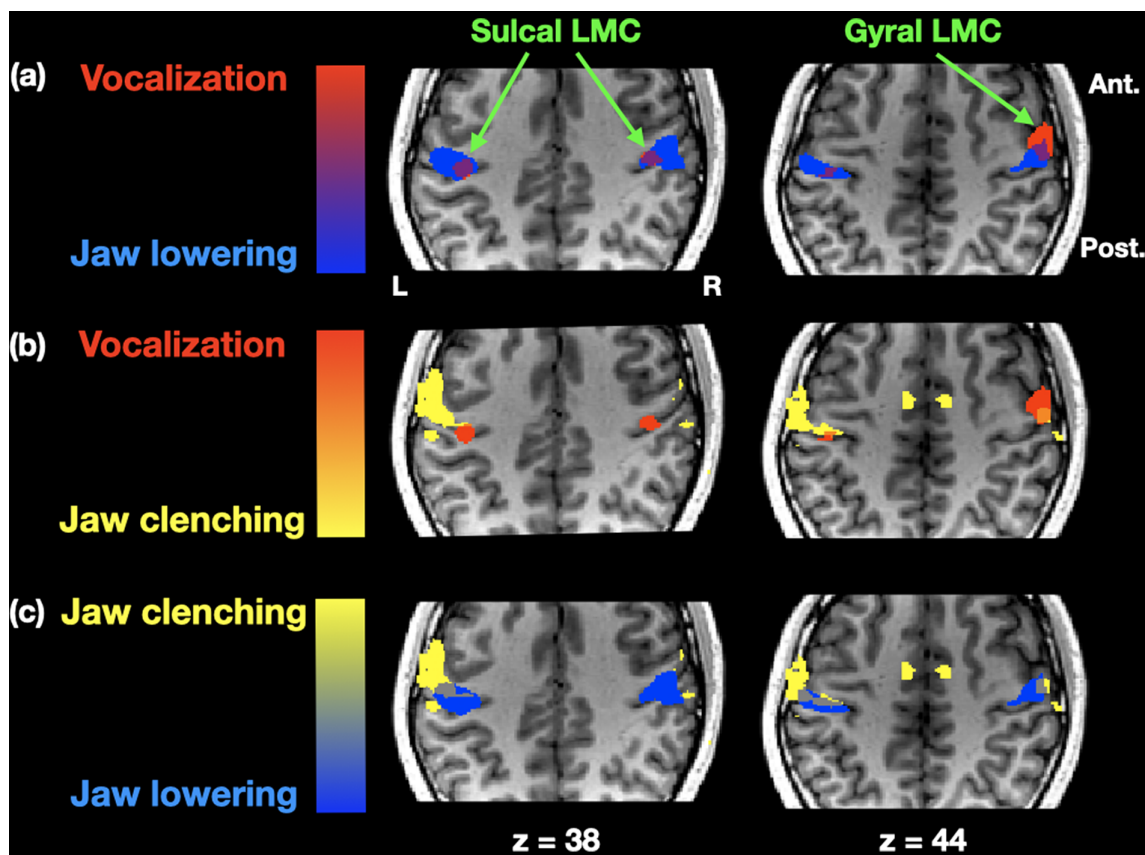


FIGURE 1 fMRI results for vocalization and jaw movement. The results are shown as logical images comparing pairs of analyses, where red, vocalization, blue, jaw lowering, and yellow, jaw clenching. Results are shown for two axial slice-levels, where the left side of the slice is the left side of the brain. Results are registered onto the anatomical MRI of one of the participants in the study. Ant., anterior; LMC, larynx motor cortex; post., posterior [Color figure can be viewed at wileyonlinelibrary.com]

peaks as the “sulcal” and “gyral” components, respectively, of the dorsal LMC. Next, Figure 1a demonstrates that the activation pattern for jaw lowering fully encompassed the sulcal LMC in both hemispheres, with nearly identical sulcal peaks bilaterally as those for vocalization (Table 1). Jaw lowering also included a major peak directly lateral to the LMC in both hemispheres that was not engaged during vocalization, but that was shared with jaw elevation (see below).

Figure 1b shows that jaw elevation through clenching activated a similarly expansive portion of primary motor cortex as jaw lowering, but demonstrated a separation from both vocalization and jaw lowering. Jaw elevation showed minimal overlap with the sulcal LMC, although it gave a weak peak in the left hemisphere (see Table 1). More overlap was seen with the gyral LMC peak, but only in the right hemisphere, which was the hemisphere where vocalization gave its

more extensive activation. Jaw elevation gave an overall left-dominant activation pattern, with its major activation peak occurring lateral and anterior to the sulcal LMC.

Figure 1c demonstrates that there was a distinction between the two dimensions of jaw movement. Jaw elevation gave a large peak in the left hemisphere that was absent in jaw lowering (and vocalization). It was located anterior to the principal peaks for jaw lowering. This location is very close to an activation peak for lip movement reported in Brown et al. (2008) and Grabski et al. (2012). Overlapping activations between jaw elevation and lowering were seen at the location mentioned above that is directly lateral to the sulcal LMC. Overlap was also observed at a dorsal location in the left hemisphere (−50, −13, 50) that was not present in vocalization. Jaw elevation showed an overall left-dominant profile in this experiment, compared to the more bilateral profile for jaw lowering.

In order to quantify voice/jaw overlap in the primary motor cortex proper (BA 4), we carried out an ROI analysis using the peak activation coordinates for the left and right sulcal LMC during vocalization (Figure 2). Jaw lowering showed significantly greater activity in the sulcal LMC of both hemispheres than did jaw clenching ($p < .01$ for the left hemisphere, and $p < .001$ for the right hemisphere). Regarding the gyral LMC (BA 6), a similar trend was seen in the right hemisphere ($p < .08$), although it was not statistically significant, nor was the effect in the left hemisphere ($p < .52$).

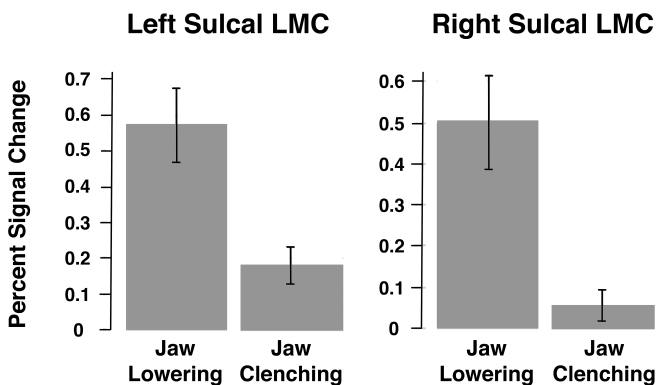


FIGURE 2 ROI analysis for jaw movement in the sulcal LMC. Percent signal change is shown for the two major dimensions of jaw movement in the left and right sulcal LMC. The ROI coordinate for the left hemisphere is −41, −19, 38, while that for the right hemisphere is 42, −19, 38 (Talairach coordinates for both)

4 | DISCUSSION

In exploring the conditions necessary to create a speech-ready brain in humans, we have provided neural evidence for voice/jaw somatotopic overlap in the primary motor cortex, where this overlap

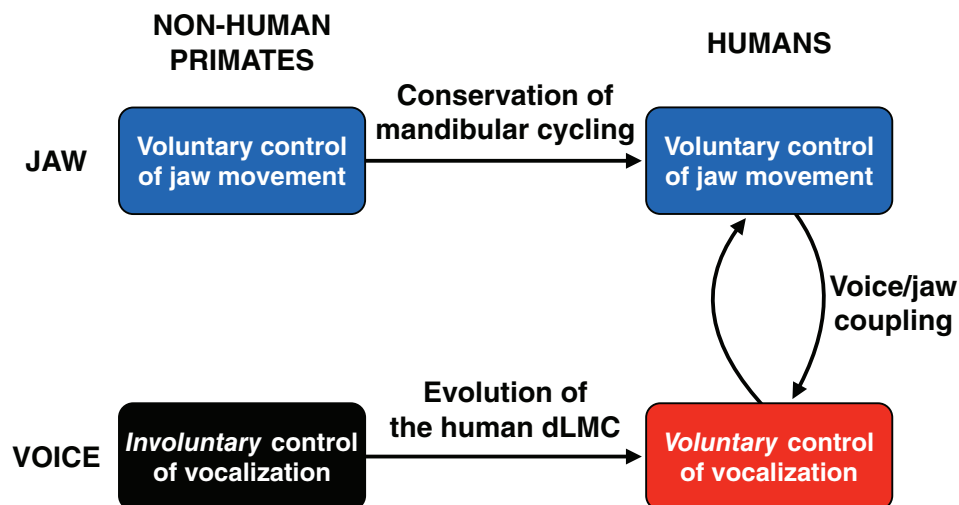


FIGURE 3 Implications of the neuroimaging data for the evolution of speech. The model presented here proposes that there was phylogenetic conservation in the control of the jaw muscles for visuofacial communication, but phylogenetic discontinuity in the voluntary control of vocalization, as mediated by the evolution of the human-specific dorsal larynx motor cortex, ultimately leading to a coupling between vocalization and mandibular oscillations (absent in nonhuman primates) to create the characteristic syllabic structure of speech. dLMC, dorsal larynx motor cortex [Color figure can be viewed at wileyonlinelibrary.com]

TABLE 1 Activation coordinates in the motor cortex for vocalization and jaw movement

	Vocalization				Jaw lowering				Jaw clenching			
	x	y	z	t	x	y	z	t	x	y	z	t
Sulcal LMC	-41	-19	38	4.29	-41	-18	38	6.64	-39	-18	36	4.42
(BA 4/3)	42	-19	38	3.68	42	-19	38	5.63				
	46	-12	41	3.51								
Gyral LMC	-56	-5	43	4.84								
(BA 6)	55	-7	45	4.45	58	-5	40	5.27				
Jaw: Ventral					-50	-16	38	7.77	-55	-14	40	5.65
									54	-11	38	4.40
					43	-7	26	4.02	-48	-8	26	6.22
Jaw: Dorsal					-50	-13	50	5.98	-50	-13	50	5.72
Clench-specific									-54	-3	36	6.05

Note: The table presents Talairach coordinates and peak *t*-score values for vocalization, jaw lowering, and jaw elevation (clenching) in the precentral gyrus (each one contrasted with fixation), FDR corrected $q < 0.05$, $k = 4$.

Abbreviations: BA, Brodmann area; LMC, larynx motor cortex.

is seen more for the jaw lowering muscles that are used for articulation than for the jaw elevator muscles that are used for chewing, as would be expected for a model in which this overlap was driven evolutionarily by syllable generation for speech production, such as MacNeilage's frame/content model (MacNeilage, 1998, 2008). In addition, we performed the first contrast between the jaw-elevating and jaw-lowering muscles in a human neuroimaging experiment. Consistent with the literature on jaw movement in great apes (Leyton & Sherrington, 1917), we found that the jaw elevator muscles that are used for mastication were localized slightly more anteriorly compared to the jaw depressor muscles that are used for speech articulation. The latter overlapped with the sulcal LMC region that was activated for vocalization in the absence of jaw movement. Hence, the analysis suggests that much about the cortical organization of jaw movement has been conserved between humans and nonhuman primates, and that the critical change for the evolution of the speech-ready brain was the novel emergence of the dorsal LMC in the human motor cortex and its coupling to the mechanisms for jaw movement, as well as its coupling with expiration (Loucks et al., 2007).

4.1 | Somatotopy of the jaw in relation to the larynx

While the majority of human neuroimaging studies of jaw movement have looked at jaw elevation alone in relation to chewing and biting force (Iida et al., 2010, 2014; Jiang et al., 2010, 2015; Lotze et al., 2017; Onozuka et al., 2002, 2003; Quintero, Ichescio, Myers, Schutt, & Gerstner, 2013; Takahashi, Miyamoto, Terao, & Yokoyama, 2007; Wong, Dziedzic, Talavage, Romito, & Byrd, 2011), Grabski et al. (2012) carried out the only prior study of jaw lowering, and demonstrated overlap with the motor-cortex peaks for vowel vocalization. We replicated this finding, and additionally showed for the first time that the larynx more strongly overlaps with the

depressor muscles of the jaw, compared to the elevator muscles, especially in the sulcal LMC (Figure 2). This location corresponds to the motor cortex proper (BA 4) and to the location of the LMC deep in the central sulcus, as described by Loucks et al. (2007) and Brown et al. (2008). A second region of motor-cortical overlap between the larynx and jaw was seen in the gyral LMC. However, there was less specificity for the jaw muscles here, where the larynx showed overlap with both the elevators and depressors of the jaw. The results in the gyral LMC were complicated by lateralization effects in this region, with a right-lateralized pattern for vocalization, but a left lateralized pattern for jaw elevation (see Table 1 and Figure 1b). However, the findings overall revealed that both sub-regions of the human dLMC showed overlap with the jaw muscles, with the clearest muscle differentiation in the region of the sulcal LMC.

The jaw muscles showed both overlap and distinction among themselves. A common area of activation across both clenching and lowering was found directly lateral to the sulcal LMC, with *x* coordinates in the 50's. This area has been reported in numerous studies of jaw clenching (Iida et al., 2010, 2014; Onozuka et al., 2002, 2003; Quintero et al., 2013; Takahashi et al., 2007; Wong et al., 2011). Our results and those of Grabski et al. (2012) showing activations in this region for jaw lowering suggest that this may be a general jaw area for controlling both major dimensions of jaw movement. Beyond such overlap, we also observed a degree of somatotopic separation between the jaw elevators and depressors in the motor cortex, with the elevators being slightly anterior to the depressors. This anterior peak has been seen in several studies of jaw clenching (Iida et al., 2014; Wong et al., 2011). This pattern reveals an evolutionary conservation in the neural representation of the jaw muscles between humans and great apes, as based on Leyton and Sherrington's (1917) demonstration that the jaw elevators are localized anteriorly and dorsally to the jaw depressors in the chimpanzee motor cortex. Given that the jaw area of the motor cortex provides the neural basis for the voluntary control of visuofacial gesturing and

mandibular oscillations, this similarity between species in the organization of the jaw muscles in the motor cortex argues for conservation in the voluntary control of the jaw muscles in humans and great apes for visuofacial gesturing, which is central to frame/content theory of speech evolution. This is also supported by the similarity between the temporal dynamics of lip smacking in Old World monkeys and syllable production in humans (Ghazanfar et al., 2012). In contrast to this continuity, there is a significant evolutionary discontinuity in the location of the dorsal LMC, which is situated in the expected primate location of the ventral motor cortex in chimpanzees (Leyton & Sherrington, 1917), but is localized far more dorsally in the human motor cortex, close to the lip representation (Brown et al., 2008) and the jaw representation (Grabski et al., 2012 and the present study).

This observation of larynx/jaw overlap is perhaps less surprising when we consider that some of the jaw muscles function as extrinsic laryngeal muscles. In particular, several of the jaw depressor muscles are laryngeal elevator muscles that move the entire larynx upward in the neck. Belyk and Brown (2014) demonstrated that activation of the extrinsic muscles of the larynx recruited the dLMC, in addition to more-ventral parts of the motor cortex. The current results might shed light on those findings by demonstrating somatotopic overlap between the larynx and the jaw depressor muscles, the latter of which serve as extrinsic laryngeal muscles. The present work contributes to a view of the multifunctionality of the dLMC in humans (Belyk & Brown, 2017). Not only is this area activated during vocalization, but also during expiration, extrinsic movement of the larynx within the vocal tract, and now a critical aspect of articulation that MacNeilage (1998) refers to as syllable framing through jaw movement. We previously reported on the proximity of the larynx area to the lip representation (Brown et al., 2008; see also Grabski et al., 2012). The novel human dLMC seems to be a convergence zone in which the three principal components of vocalization—expiration, phonation, and articulation—have developed a degree of neural overlap that is not seen in any other primate species.

It is worth noting that the two sets of muscles that serve as antagonists for jaw movement are quite distant from one another in the body: the jaw elevators are located in the face and head area, whereas the jaw depressors are located in the neck. Otherwise stated, the elevator muscles are supra-mandibular, whereas the depressor muscles are infra-mandibular, having attachments to the hyoid bone, which is the only bony component of the larynx. The laryngeal muscles are much closer to the jaw depressors than they are to the jaw elevators in terms of anatomical location. It is therefore interesting that the human-specific larynx area of the motor cortex is located closer to the representation for the jaw depressors than to that for the jaw elevators, paralleling the anatomical proximity of the larynx to the infra-mandibular depressor muscles themselves. However, this cortical convergence of jaw and larynx is not reflected in the brain stem. The nucleus ambiguus for the control of the laryngeal muscles is quite removed from the trigeminal motor nucleus for the control of the jaw muscles, although both nuclei have a common embryological origin as components of the branchiomotor system, and both occur in a vertical cell column in the brain stem for the special visceral efferent system (Finger, 1993).

4.2 | Implications for the origins of speech

The present work provides support for the contention that changes to the brain, rather than changes to the vocal tract, were the driving forces for the evolution of speech (Fitch et al., 2016). We argue that the critical change was the evolutionary emergence of a neural system for the voluntary control of vocalization—namely the LMC—and its coupling to a pre-existing but nonvocal system for voluntary control of jaw movement, as shown in the model diagram in Figure 3. MacNeilage's frame/content theory (MacNeilage, 1998) proposes that the mandibular oscillations that underlie the universal CV syllable structure of human speech were evolutionarily derived from a conserved system of visuofacial communicative cyclicities in ancestral humans, similar to the lip smacks of modern-day primates. However, the transition from the oral gestures of lip smacks to the syllables of speech required the addition of vocalization and its respiratory drive force onto this mandibular oscillatory system. We propose that this change was mediated by the evolutionary emergence of the human-specific LMC and its linkage to the neural control of jaw movement, most especially jaw depression. The emergence of this area not only permitted the transition from involuntary to voluntary control of vocalization and the transition from the absence to the presence of vocal learning (Belyk & Brown, 2017), but it also permitted the coupling of mandibular oscillations with vocalization in order to create the characteristic syllable structure of human speech. Otherwise stated, the dorsal LMC converted a voluntary but voiceless articulatory gesture into a voluntary and vocal articulatory gesture (Figure 3). This model also sheds light on the conundrum of why the human dorsal LMC came to be situated in the specific location where it resides in the motor cortex, which diverges considerably from the location expected from homology with nonhuman primates (Leyton & Sherrington, 1917). We hypothesize that the LMC came to be situated where it is so as to place circuits for voluntary control of vocalization proximate to cortical areas mediating not just articulation in general, but mandibular cycling in particular, permitting the evolution of syllable framing via voice/jaw coupling.

4.3 | Branchiomotor confluence

Three branchiomotor nuclei in the human brainstem are derived from the ancestral vertebrate system for innervating the gill arches of fish (Chandrasekhar, 2004; Guthrie, 2007). These are the nucleus ambiguus that innervates the laryngeal muscles, the trigeminal motor nucleus that innervates the jaw muscles (both the depressors and the elevators), and the facial motor nucleus that innervates the lip muscles and the other facial muscles. The tongue is not part of this system, since the hypoglossal nucleus is not a component of the branchiomotor system. We suggested previously that the LMC's location in the motor cortex may have resulted from a cortical confluence of the three branchiomotor systems for the larynx, jaw, and lips, respectively (Belyk & Brown, 2017). This idea is supported by the fact that the trigeminal motor nucleus, facial motor nucleus, and nucleus

ambiguous are organized as a single rostral-caudal cell column in the ventral brain stem (Finger, 1993). Branchiomotor confluence might explain why the larynx, jaw, and lips are very close to one another in the motor cortex. However, a critical exception to this pattern is the representation of the pharyngeal muscles for swallowing, which are also derived from the gill arches. While these muscles receive innervation from the nucleus ambiguus, via the pharyngeal division of the vagus nerve, the pharyngeal representation in the motor cortex is at the ventral-most extreme of the motor strip, far removed from the cortical confluence of the LMC, jaw area, and lip area. This might be accounted for by the fact that swallowing is not considered to be a critical component of vocalization, but instead serves a more vegetative function. Hence, the convergence of the larynx, jaw, and lips in the primary motor cortex might be related to the convergent activation of these muscles during vocal communication.

4.4 | Limitations

Neuroimaging studies of jaw movement have reported variable activation peaks within the motor cortex, making it challenging to perform a fine-grained spatial comparisons among the studies. In addition, while Grabski et al. (2012) reported similar coordinates in the motor cortex between vocalization and jaw lowering, as we did in the current study, their peak coordinates were about 10 mm anterior to ours. Moreover laterality effects complicated the logical analyses shown in Figure 1. For example, in the region of the gyrus LMC, vocalization showed only a right-lateralized activation, while jaw clenching showed only a left-lateralized activation. Most previous studies of jaw clenching have shown bilateral activations in the motor cortex, and so we are not clear on why we observed a more left-lateralized profile in the current study. Had the jaw activations been bilateral in this region, there would have been ever more overlap with vocalization than is currently being reported.

5 | CONCLUSIONS

Using fMRI, we demonstrated overlap between the localization of the voice (larynx) and the localization of the two principal dimensions of jaw movement in the human motor cortex. The results showed a greater overlap of the voice with the jaw depressor muscles involved in speech articulation than with the jaw elevator muscles involved in generating chewing force during mastication. Given the hypothesis that the dorsal LMC is a human novelty that was part of the mechanism for the evolution of vocal production learning, we propose that its overlap with the jaw-lowering mechanism is related to the evolution of syllable structure, which came about through the coupling of vocalization with a mandibular oscillatory cycle so as to generate the characteristic consonant/vowel cycling of speech. The dorsal LMC may have come to acquire its novel location in the human brain in order to optimize the coupling between phonation and articulation in speech production, thereby establishing the conditions for a speech-ready brain.

ACKNOWLEDGMENTS

This work was funded by a grant from the Natural Sciences and Engineering Research Council (NSERC) of Canada to Steven Brown (371336).

CONFLICT OF INTEREST

The authors declare no conflict of interest.

DATA AVAILABILITY STATEMENT

The data that support the findings of this study are openly available in Dryad at doi:10.5061/dryad.np5hqbzpm

PEER REVIEW

The peer review history for this article is available at <https://publons.com/publon/10.1002/cne.24997>.

ORCID

Steven Brown  <https://orcid.org/0000-0002-2457-7942>

REFERENCES

- Ardran, G., & Kemp, F. (1952). The protection of the laryngeal airway during swallowing. *British Journal of Radiology*, 25, 406–416.
- Belyk, M., & Brown, S. (2014). Somatotopy of the extrinsic laryngeal muscles in the human sensorimotor cortex. *Behavioural Brain Research*, 270, 364–371. <https://doi.org/10.1016/j.bbr.2014.05.048>
- Belyk, M., & Brown, S. (2017). The origins of the vocal brain in humans. *Neuroscience and Biobehavioral Reviews*, 77, 177–193. <https://doi.org/10.1016/j.neubiorev.2017.03.014>
- Bergman, T. J. (2013). Speech-like vocalized lip-smacking in geladas. *Current Biology*, 23, R268–R269. <https://doi.org/10.1016/j.cub.2013.02.038>
- Bianchi, S., Reyes, L. D., Hopkins, W. D., Tagliatalata, J. P., & Sherwood, C. C. (2016). Neocortical grey matter distribution underlying voluntary, flexible vocalizations in chimpanzees. *Scientific Reports*, 6, 4–10. <https://doi.org/10.1038/srep34733>
- Boë, L. J., Sawallis, T. R., Fagot, J., Badin, P., Barbier, G., Captier, G., ... Schwartz, J. L. (2019). Which way to the dawn of speech?: Reanalyzing half a century of debates and data in light of speech science. *Science Advances*, 5(12), eaaw3916. <https://doi.org/10.1126/sciadv.aaw3916>
- Bouchard, K. E., Mesgarani, N., Johnson, K., & Chang, E. F. (2013). Functional organization of human sensorimotor cortex for speech articulation. *Nature*, 495(7441), 327–332. <https://doi.org/10.1038/nature11911>
- Breshears, J. D., Molinaro, A. M., & Chang, E. F. (2015). A probabilistic map of the human ventral sensorimotor cortex using electrical stimulation. *Journal of Neurosurgery*, 123(2), 340–349. <https://doi.org/10.3171/2014.11.JNS14889.DISCLOSURE>
- Brown, S., Ngan, E., & Liotti, M. (2008). A larynx area in the human motor cortex. *Cerebral Cortex*, 18(4), 837–845. <https://doi.org/10.1093/cercor/bhm131>
- Chandrasekhar, A. (2004). Turning heads: Development of vertebrate branchiomotor neurons. *Developmental Dynamics*, 229(1), 143–161. <https://doi.org/10.1002/dvdy.10444>
- Conant, D., Bouchard, K. E., & Chang, E. F. (2014). Speech map in the human ventral sensory-motor cortex. *Current Opinion in Neurobiology*, 24(1), 63–67. <https://doi.org/10.1016/j.conb.2013.08.015>
- Dichter, B. K., Breshears, J. D., Leonard, M. K., & Chang, E. F. (2018). The control of vocal pitch in human laryngeal motor cortex. *Cell*, 174(1), 21–31.e9. <https://doi.org/10.1016/j.cell.2018.05.016>

- Finger, T. E. (1993). What's so special about special visceral? *Acta Anatomica*, 148, 132–138.
- Fitch, W. T., De Boer, B., Mathur, N., & Ghazanfar, A. A. (2016). Monkey vocal tracts are speech-ready. *Science Advances*, 2(12), e1600723. <https://doi.org/10.1126/sciadv.1600723>
- Fitch, W. T., & Hauser, M. D. (2002). Unpacking "honesty": Vertebrate vocal production and the evolution of acoustic signals. In A. M. Simmons, A. N. Popper, & R. R. Fay (Eds.), *Acoustic communication* (pp. 65–137). New York: Springer.
- Ghazanfar, A. A., & Takahashi, D. Y. (2014). Facial expressions and the evolution of the speech rhythm. *Journal of Cognitive Neuroscience*, 26, 1196–1207.
- Ghazanfar, A. A., Takahashi, D. Y., Mathur, N., & Fitch, W. T. (2012). Cineradiography of monkey lip-smacking reveals putative precursors of speech dynamics. *Current Biology*, 22(13), 1176–1182. <https://doi.org/10.1016/j.cub.2012.04.055>
- Grabski, K., Lamalle, L., Vilain, C., Schwartz, J. L., Vallée, N., Tropes, I., ... Sato, M. (2012). Functional MRI assessment of orofacial articulators: Neural correlates of lip, jaw, larynx, and tongue movements. *Human Brain Mapping*, 33(10), 2306–2321. <https://doi.org/10.1002/hbm.21363>
- Gracco, V. L., & Löfqvist, A. (1994). Speech motor coordination and control: Evidence from lip, jaw, and laryngeal movements. *Journal of Neuroscience*, 14, 6585–6597.
- Granatosky, M. C., McElroy, E. J., Laird, M. F., Iriarte-Diaz, J., Reilly, S. M., Taylor, A. B., & Ross, C. F. (2019). Joint angular excursions during cyclical behaviors differ between tetrapod feeding and locomotor systems. *Journal of Experimental Biology*, 222, jeb200451. <https://doi.org/10.1242/jeb.200451>
- Gray, H. (1918). *Anatomy of the human body* (20th ed.). Philadelphia: Lea & Febiger.
- Guthrie, S. (2007). Patterning and axon guidance of cranial motor neurons. *Nature Reviews Neuroscience*, 8(11), 859–871. <https://doi.org/10.1038/nrn2254>
- Hast, M. H., Fischer, J. M., & Wetzell, A. B. (1974). Cortical motor representation of the laryngeal muscles in *Macaca mulatta*. *Brain Research*, 73, 229–240.
- Hast, M. H., & Milojkovic, R. (1966). The response of the vocal folds to electrical stimulation of the inferior frontal cortex of the squirrel monkey. *Acta Oto-Laryngologica*, 61, 196–204.
- Hatanaka, N., Tokuno, H., Nambu, A., Inoue, T., & Takada, M. (2005). Input-output organization of jaw movement-related areas in monkey frontal cortex. *Journal of Comparative Neurology*, 492(4), 401–425. <https://doi.org/10.1002/cne.20730>
- Hopkins, W. D., Tagliatalata, J. P., & Leavens, D. A. (2007). Chimpanzees differentially produce novel vocalizations to capture the attention of a human. *Animal Behaviour*, 73(2), 281–286.
- Huang, C. S., Hiraba, H., Murray, G. M., & Sessle, B. J. (1989). Topographical distribution and functional properties of cortically induced rhythmic jaw movements in the monkey (*Macaca fascicularis*). *Journal of Neurophysiology*, 61(3), 635–650. <https://doi.org/10.1152/jn.1989.61.3.635>
- Iida, T., Kato, M., Komiyama, O., Suzuki, H., Asano, T., Kuroki, T., ... Kawara, M. (2010). Comparison of cerebral activity during teeth clenching and fist clenching: A functional magnetic resonance imaging study. *European Journal of Oral Sciences*, 118(6), 635–641. <https://doi.org/10.1111/j.1600-0722.2010.00784.x>
- Iida, T., Overgaard, A., Komiyama, O., Weibull, A., Baad-Hansen, L., Kawara, M., ... Svensson, P. (2014). Analysis of brain and muscle activity during low-level tooth clenching: A feasibility study with a novel biting device. *Journal of Oral Rehabilitation*, 41(2), 93–100. <https://doi.org/10.1111/joor.12128>
- Iwatsubo, T., Kuzuhara, S., & Kanemitsu, A. (1990). Corticofugal projections to the motor nuclei of the brainstem and spinal cord in humans. *Neurology*, 40, 309–312.
- Jackendoff, R. (2002). *Foundations of language*. Oxford: Oxford University Press.
- Jiang, H., Liu, H., Liu, G., Jin, Z., & Liu, X. (2010). The effects of chewing-side preference on human brain activity during tooth clenching: An fMRI study. *Journal of Oral Rehabilitation*, 37(12), 877–883. <https://doi.org/10.1111/j.1365-2842.2010.02115.x>
- Jiang, H., Liu, H., Liu, G., Jin, Z., Wang, L., Ma, J., & Li, H. (2015). Analysis of brain activity involved in chewing-side preference during chewing: An fMRI study. *Journal of Oral Rehabilitation*, 42(1), 27–33. <https://doi.org/10.1111/joor.12224>
- Jürgens, U. (1974). On the elicibility of vocalization from the cortical larynx area. *Brain Research*, 81(3), 564–566.
- Kuypers, H. G. J. M. (1958a). Corticobulbar connexions to the pons and lower brain-stem in man. *Brain*, 81(3), 364–388.
- Kuypers, H. G. J. M. (1958b). Some projections from the peri-central cortex to the pons and lower brain stem in monkey and chimpanzee. *Journal of Comparative Neurology*, 110, 221–255.
- Leyton, S., & Sherrington, C. (1917). Observations on the excitable cortex of the chimpanzee, organ-utan, and gorilla. *Experimental Physiology*, 11(2), 135–222.
- Loh, K. K., Petrides, M., Hopkins, W. D., Procyk, E., & Amiez, C. (2017). Cognitive control of vocalizations in the primate ventrolateral-dorsomedial frontal (VLF-DMF) brain network. *Neuroscience and Biobehavioral Reviews*, 82, 32–44. <https://doi.org/10.1016/j.neubiorev.2016.12.001>
- Lotze, M., Domin, M., & Kordass, B. (2017). Symmetry of fMRI activation in the primary sensorimotor cortex during unilateral chewing. *Clinical Oral Investigations*, 21(4), 967–973. <https://doi.org/10.1007/s00784-016-1858-4>
- Loucks, T. M. J., Poletto, C. J., Simonyan, K., Reynolds, C. L., & Ludlow, C. L. (2007). Human brain activation during phonation and exhalation: Common volitional control for two upper airway functions. *NeuroImage*, 36(1), 131–143. <https://doi.org/10.1016/j.neuroimage.2007.01.049>
- MacNeilage, P. F. (1998). The frame/content theory of evolution of speech production. *Behavioral and Brain Sciences*, 21(1998), 499–546.
- MacNeilage, P. F. (2008). *The origin of speech*. Oxford: Oxford University Press.
- Maddieson, I. (2005a). Consonant inventories. In M. Haspelmath, M. S. Dryer, D. Gil, & B. Comrie (Eds.), *The world atlas of language structures* (pp. 10–13). Oxford: Oxford University Press.
- Maddieson, I. (2005b). Vowel quality inventories. In M. Haspelmath, M. S. Dryer, D. Gil, & B. Comrie (Eds.), *The world atlas of language structures* (pp. 14–17). Oxford: Oxford University Press.
- Morrill, R. J., Paukner, A., Ferrari, P. F., & Ghazanfar, A. A. (2012). Monkey lipsmacking develops like the human speech rhythm. *Developmental Science*, 15(4), 557–568.
- Onozuka, M., Fujita, M., Watanabe, K., Hirano, Y., Niwa, M., Nishiyama, K., & Saito, S. (2002). Mapping brain region activity during chewing: A functional magnetic resonance imaging study. *Journal of Dental Research*, 81(11), 743–746. <https://doi.org/10.1177/154405910208101104>
- Onozuka, M., Fujita, M., Watanabe, K., Hirano, Y., Niwa, M., Nishiyama, K., & Saito, S. (2003). Age-related changes in brain regional activity during chewing: A functional magnetic resonance imaging study. *Journal of Dental Research*, 82(8), 657–660. <https://doi.org/10.1177/154405910308200817>
- Penfield, W., & Boldrey, E. (1937). Somatic motor and sensory representations in the cerebral cortex of man as studied by electrical stimulation. *Brain*, 60, 389–443.
- Pfenning, A. R., Hara, E., Whitney, O., Rivas, M. V., Wang, R., Roulhac, P. L., ... Jarvis, E. D. (2014). Convergent transcriptional specializations in the brains of humans and song-learning birds. *Science*, 346(6215), 1256846. <https://doi.org/10.1126/science.1256846>

- Quintero, A., Ichesco, E., Myers, C., Schutt, R., & Gerstner, G. E. (2013). Brain activity and human unilateral chewing: An fMRI study. *Journal of Dental Research*, 92(2), 136–142. <https://doi.org/10.1177/0022034512466265>
- Rödel, R. M. W., Olthoff, A., Tergau, F., Simonyan, K., Kraemer, D., Markus, H., & Kruse, E. (2004). Human cortical motor representation of the larynx as assessed by transcranial magnetic stimulation (TMS). *Laryngoscope*, 114(5), 918–922. <https://doi.org/10.1097/00005537-200405000-00026>
- Seikel, J., King, D., & Drumwright, D. (2010). *Anatomy & physiology for speech, language, and hearing* (4th ed.). Clifton Park, NY: Delmar, Cengage Learning.
- Sessle, B. J., Avivi-Arber, L., & Murray, G. M. (2015). Motor control of masticatory muscles. In L. K. McLoon & F. H. Andrade (Eds.), *Craniofacial muscles: A new framework for understanding the effector side of craniofacial muscle control* (pp. 111–130). New York: Springer Science+Business Media.
- Sessle, B. J. (2011). Face sensorimotor cortex: Its role and neuroplasticity in the control of orofacial movements. *Progress in Brain Research*, 188, 71–82. <https://doi.org/10.1016/B978-0-444-53825-3.00010-3>
- Simonyan, K., & Horwitz, B. (2011). Laryngeal motor cortex and control of speech in humans. *The Neuroscientist*, 17(2), 197–208. <https://doi.org/10.1177/1073858410386727>
- Simonyan, K., Ostuni, J., Ludlow, C. L., & Horwitz, B. (2009). Functional but not structural networks of the human laryngeal motor cortex show left hemispheric lateralization during syllable but not breathing production. *Journal of Neuroscience*, 29(47), 14912–14923. <https://doi.org/10.1523/JNEUROSCI.4897-09.2009>
- Takahashi, T., Miyamoto, T., Terao, A., & Yokoyama, A. (2007). Cerebral activation related to the control of mastication during changes in food hardness. *Neuroscience*, 145(3), 791–794. <https://doi.org/10.1016/j.neuroscience.2006.12.044>
- Talairach, J., & Tournoux, P. (1988). Co-planar stereotaxic atlas of the human brain. New York: Thieme Medical Publishers.
- Townsend, S., & Zuberbuhler, K. (2009). Audience effects in chimpanzee copulation calls. *Communicative and Integrative Biology*, 2(3), 282–284. <https://doi.org/10.4161/cib.2.3.6796>
- Wong, D., Dziedzic, M., Talavage, T. M., Romito, L. M., & Byrd, K. E. (2011). Motor control of jaw movements: An fMRI study of para-functional clench and grind behavior. *Brain Research*, 1383, 206–217. <https://doi.org/10.1016/j.brainres.2011.01.096>

SUPPORTING INFORMATION

Additional supporting information may be found online in the Supporting Information section at the end of this article.

How to cite this article: Brown S, Yuan Y, Belyk M. Evolution of the speech-ready brain: The voice/jaw connection in the human motor cortex. *J Comp Neurol*. 2021;529:1018–1028. <https://doi.org/10.1002/cne.24997>